CHAPTER 63

History and examination of the abdomen

Learning objectives

To learn:
- The art and science of history-taking in a patient with abdominal complaints

To be able to:
- Recognise the organ or system responsible for the clinical features

To understand:
- The pathophysiological basis of common abdominal symptoms and signs as the pathway to clinical diagnosis

To be aware of:
- Leading questions and relevant physical signs based on the organ or system affected

INTRODUCTION

Abdominal symptoms are a frequent cause for surgical consultation. The underlying cause may be acute, presenting with the euphemistically termed 'acute abdomen'; subacute, indicating an evolving disorder; or longstanding, suggesting a functional or degenerative condition. Occasionally symptoms are due to disorders outside the abdomen, in which case the term 'referred' is used; for example, epigastric pain experienced as a result of a myocardial infarction.

At first presentation, a detailed clinical history and careful clinical examination are essential to establish a differential diagnosis, which, in turn, leads to appropriate triage into urgent and non-urgent investigation and subsequent treatment.

The advent of telemedicine and online remote consultation does not alter the basic art and science of consultation; however, the inability to perform a 'physical' examination may hamper arrival at a proper diagnosis. In such a scenario, a patient should be asked to come for a face-to-face consultation, physical examination and necessary investigations. It is vital to not miss a potentially seriously illness that needs urgent attention.

GATHERING INFORMATION

The experienced clinician will recognise the acuity and severity of the patient's condition even before a history has been taken. Initial observation provides clues to the direction that the history should take: general appearance, gait, position in bed, facial expression and tone of speech all provide useful hints. In an acute presentation, it is important to realise that the patient will feel anxious and vulnerable and may well be in severe pain; therefore, clinicians should introduce themselves, try to comfort the patient and gain the patient's confidence. Clinicians should put the patient at ease and seek permission to begin the consultation in ensured privacy. If a patient is still uncomfortable or reticent, the presence of a close family member as a chaperone can help. A tense patient without a relaxed abdominal wall will substantively affect the accuracy of the clinical examination. This is particularly important in a busy emergency department where the patient is only one among many.

Summary box 63.1

Importance of history and examination
- There is no substitute for a detailed history and thorough clinical examination
- The temptation to proceed to a diagnostic investigation such as abdominal ultrasound or computed tomography scan without clinical examination should be resisted

Obtaining a history

Presenting complaint

To establish the presenting complaint one should start with an open question inviting the patient to explain the reason for seeking medical advice. The patient must be allowed to explain the presenting complaint without interruption, after which carefully directed questions are used to further refine the history (Osler). Clues from these will allow identification of a

Sir William Osler, 1849–1919, Canadian Physician, initiated bedside clinical training for medical students at Johns Hopkins School of Medicine, Baltimore, MD, USA. 'Listen to the patient; he is giving you the diagnosis'.

likely organ or system responsible for the patient's symptoms, which then guides subsequent clinical examination and investigation to arrive at a probable diagnosis. History taking can be forwards and backwards, but its record should be structured.

In the acute situation, pain is the most common presenting feature. The classic features of site, nature, onset, duration, radiation and aggravating or relieving features of the pain should be established. In non-acute presentations, anorexia, weight loss, jaundice, altered bowel habit, blood loss and fatigue are all features that should be questioned.

Past medical history

The past history is important because it may have a bearing on the diagnosis and management. A history of previous similar episodes or past abdominal surgery often guides the diagnosis; for example, adhesive small bowel obstruction in a patient with a history of laparotomy or recurrent left iliac fossa pain in a patient with a past history of diverticulitis. Some symptoms and signs may be due to cardiac, respiratory, haematological conditions, such as abdominal pain in sickle cell crisis or acute epigastric pain in diabetic ketoacidosis.

Recurrent right iliac fossa pain may suggest a past history of appendicitis, Crohn's disease or in some regions amoebic typhlitis or ileocaecal tuberculosis. A positive history of tuberculosis can help in differential diagnoses in many patients. Efforts should be made to obtain previous medical records and investigations.

Drug history and allergies

Some drugs will have an effect on the symptoms and signs or may have to be discontinued before surgery. For example, a patient with bleeding who is taking a β-blocker will not have tachycardia proportionate to the blood loss; a patient taking long-term corticosteroids will need intravenous steroid supplementation to prevent an adrenal crisis in the perioperative period; a patient taking anticoagulant drugs may require reversal of the effects before surgical intervention. Patients with diabetes will require strict glycaemic control with sliding scale insulin in the perioperative period. Detailed enquiry about adverse reactions to anaesthetics or medications can prevent such problems later on.

Social history

The use of alcohol and illicit drugs, smoking and occupation are important. A history of family background and domestic support will guide the planning of discharge after surgery.

Family history

It is important to establish a family history of similar or related conditions, particularly cancer, inflammatory bowel disease, endocrine disease (e.g. hyperparathyroidism causing hypercalcaemia or renal calculi) and genetic disorders, including adverse reactions to anaesthetics or medications.

Review of the systems

A systems review should highlight any comorbid disease, such as cardiac, vascular, respiratory or endocrine problems; these have grave implications for the safety of any surgical intervention.

Summary box 63.2

Principles of history taking

- Identify the reason for consultation – the presenting complaint
- Determine the onset, duration and evolution of the symptoms
- Deduce the most likely organ or system affected
- Refine the history with relevant direct questions
- Establish relevant past, social, family, drug and allergy history
- Complete with a thorough review of other systems
- Devise a list of differential diagnoses

CLINICAL PRESENTATION OF ABDOMINAL PROBLEMS

Pain, weight loss, anorexia or vomiting, jaundice, abdominal bloating/distension, presence of a lump, alteration of bowel habit and blood loss or anaemia are the common clinical presentations of abdominal pathology. It is important to be vigilant about insidious presentations of malignancies. Classic examples are right colon cancer presenting with symptoms of anaemia, metastatic liver cancer with weight loss, gastric cancer with loss of appetite, ovarian cancer with abdominal distension and malignant obstruction of the extrahepatic biliary tree presenting with jaundice.

Abdominal pain

Pain is the most common of all abdominal symptoms and may be due to inflammatory, infective, obstructive, neurogenic, neoplastic or ischaemic pathology. Sometimes no organic cause can be found, a situation often labelled as 'functional or non-specific abdominal pain'. Improved understanding of pain pathways and the relationship with the gastrointestinal microbiome is likely to provide a more precise diagnosis, particularly in common 'functional' disorders such as non-ulcer dyspepsia and irritable bowel syndrome (IBS) (see *Chapter 73*).

It is essential to establish the site, nature and radiation of the pain, the rapidity of onset and associated or relieving features such as food intake and or vomiting. Thus biliary colic will classically result in colicky pain in the right upper quadrant of the abdomen that radiates to the angle of the scapula and is associated with food intake (which results in cholecystokinin release and gallbladder contraction). The pain of acute appendicitis starts around the umbilicus and then shifts and localises to the right iliac fossa. Acute pancreatitis often has an abrupt onset of severe epigastric pain radiating to the back, which may be similar to pain emanating from peptic ulcer perforation or a leaking aortic aneurysm. Intestinal colic is most frequently associated with periumbilical pain and abdominal distension: the more distal in the intestine the pathology, the greater the degree of distension. Vomiting is an early feature of proximal small bowel obstruction, whereas absolute constipation is an early feature of colonic obstruction. Renal or ureteric colic is intense, located in the flanks and radiating towards the lower midline and scrotum. It is usually associated with either macroscopic or microscopic haematuria.

With regard to altered bowel habit, the onset, nature, duration, type of alteration (constipation or diarrhoea) and its relationship to abdominal pain will help to differentiate organic pathology causing obstruction or inflammation (colon cancer or inflammatory bowel disease [IBD]) from functional conditions such as IBS. When patients complain of diarrhoea, they may imply different meanings – some use the term for loose stools, others may mean frequent but normal stools. A longstanding increase in frequency of stools, with left-sided abdominal pain before defecation that eases after defecation, is suggestive of IBS. However, if such symptoms are of recent onset or are associated with blood or mucus in the stools, colonic carcinoma or IBD is more likely. A history of progressive change in bowel habit with an acute presentation with abdominal pain, distension and absolute constipation suggests acute-on-chronic intestinal obstruction, often from a stenotic left colon cancer. Marked distension with tenderness over the caecal area suggests a closed-loop obstruction with impending caecal rupture. Ileocaecal tuberculosis may present as a mass in the right iliac fossa with a ball of wind and gurgle suggestive of ileal stricture.

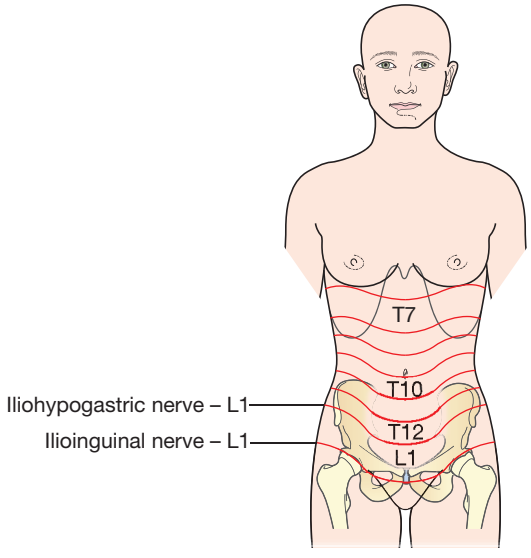

Figure 63.1 Distribution of the anterior abdominal wall dermatome and nerves.

Summary box 63.3

Classic presentations of abdominal pathology

- Obstructive and inflammatory pathology must be excluded in patients with abdominal pain and altered bowel habit as these require urgent care
- Closed-loop obstruction with tenderness in the right iliac fossa is indicative of imminent caecal rupture
- Caecal and ascending colon cancers classically present with anaemia
- Patients who have had previous abdominal surgery may have adhesions
- Check carefully for small incarcerated hernias, particularly femoral in obese patients as these may be hidden by 'abdominal panniculus'

PATHOPHYSIOLOGICAL BASIS OF COMMON ABDOMINAL SYMPTOMS AND SIGNS

The abdominal wall and parietal peritoneum are innervated by the somatic nervous system, whereas the abdominal organs and visceral peritoneum are innervated by the autonomic nervous system. Therefore pain may change in its character and distribution as the underlying pathology evolves. Visceral pain from the foregut is generally felt in the epigastrium, in the periumbilical area from the midgut and in the suprapubic area from the hindgut.

The skin and the muscles of the abdominal wall are supplied by the lateral and anterior cutaneous branches of the lower six intercostal nerves, the iliohypogastric nerve and the ilioinguinal nerve (***Figure 63.1***). The dermatome levels of the xiphoid process, umbilicus and pubis are T7, T10 and T12, respectively. The parietal peritoneum is supplied segmentally by the same nerves that innervate the overlying muscles. The central part of the diaphragmatic peritoneum is supplied by the phrenic nerve (C4); therefore, pain arising in this region is referred to the tip of the shoulder as it has the same segmental supply. The peripheral rim of the diaphragmatic peritoneum is supplied by the intercostal nerves. The obturator nerve is the principal nerve supply of the pelvic parietal peritoneum.

Pain from the viscera is principally due to ischaemia, muscle spasm or stretching of the visceral peritoneum. Unlike somatic pain, autonomic pain is deep and poorly localised. This pain is transmitted via sympathetic fibres and so is referred to the appropriate somatic distribution of that nerve root from T1 to L2. However, when an inflamed organ touches the parietal peritoneum, the pain becomes sharp and localises to the appropriate segmental dermatome of the abdominal wall. Referred pain due to irritation of the undersurface of the diaphragm by blood from a ruptured spleen can be felt at the left shoulder. Pain arising from the parietal peritoneum may radiate to the back or the front along the appropriate dermatome. This referral pattern is classically seen in acute cholecystitis when an inflamed gallbladder touches the parietal peritoneum. Pain then radiates round to the back along the involved dermatome. The overlying muscle and skin are supplied by the same nerve root, so, when the patient takes a deep breath, the tenderness in the right subcostal region is markedly increased, causing the patient to stop breathing; this is Murphy's sign. In children with abdominal pain who hold their right hip in a flexed position to obtain relief from the pain, one should suspect retrocaecal appendicitis causing irritation of the psoas muscle.

John Benjamin Murphy, 1857–1916, Professor of Surgery, Northwestern University, Chicago, IL, USA, described his sign in 1903. He was the son of immigrants fleeing the potato famine in Ireland. He was known as the 'stormy petrel' of American surgery.

Summary box 63.4

Nerves responsible for abdominal pain

- Abdominal wall and parietal peritoneum are supplied by the somatic nerves
- Abdominal organs and the visceral peritoneum are supplied by the autonomic nervous system
- Skin, muscles and parietal peritoneum are supplied by the iliohypogastric and ilioinguinal nerves and the lower six intercostal nerves
- Afferent pain fibres from the abdominal organs and visceral peritoneum travel with sympathetic nerves

Summary box 63.5

Specific characteristics of abdominal pain

- Visceral pain arises from ischaemia, muscle spasm or stretching of the visceral peritoneum
- Autonomic pain, deep and poorly localised, is referred to the equivalent somatic distribution of that nerve root from T1 to L2
- When an inflamed organ touches the parietal peritoneum, pain is then localised to the segmental dermatome of the abdominal wall
- The pain in the parietal peritoneum may radiate to back or front along the dermatome

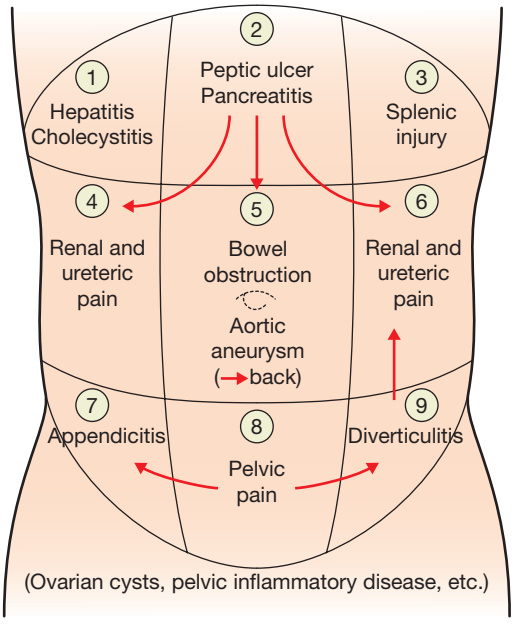

Figure 63.2 Nine sites of abdominal pain: 1, right subcostal; 2, epigastrium; 3, left subcostal; 4, right flank; 5, periumbilical; 6, left flank; 7, right iliac fossa; 8, suprapubic/hypogastrium; 9, left iliac fossa. (From Bailey and Love, 25th edn, courtesy of Mr Simon Paterson-Brown, Consultant Surgeon, Royal Infirmary of Edinburgh.)

Obstruction

Central colicky abdominal pain is a classic presentation of small bowel obstruction. The central distribution is because of the segmental nerve supply of the midgut. When the peristaltic waves hit an obstruction, the contractions increase to overcome the resistance, producing the colic. The pain reaches a crescendo and then disappears in minutes when the peristaltic wave passes. This is different from that of biliary colic. When the gallbladder contracts against a stone, pain is relatively insidious in onset and reaches its peak in about half an hour and then eases off. A basal pain persists between the bouts of colic. Pain of ureteric colic is intense, lasting 1–2 minutes along the line of the ureter.

Summary box 63.6

Colicky abdominal pain

- Pain of 'small bowel colic' comes in waves and disappears completely in minutes when the peristaltic wave ceases
- Pain of biliary colic is insidious in onset, reaches the peak in half an hour or so and does not ease off completely between spasms
- Pain of ureteric colic is intense, lasting 1–2 minutes

Rupture and perforation of organs

The urinary bladder, gallbladder and gastrointestinal tract are hollow organs that contain fluid. The gastrointestinal system also contains faeces, air and a high concentration of organisms. Trauma, ischaemia or tissue ulceration may cause perforation, with resulting leak of luminal contents with peritonitis and resulting in severe abdominal pain. This may be localised to the area immediately adjacent to the perforation (for example, in a localised perforation of an appendix) or more generalised. The initial site of onset of the pain may give a clue as to the organ involved and so help with the differential diagnosis. For example, the diagnosis of a perforated peptic ulcer is supported by a past history of ulcer-type pain followed by a sudden onset of upper abdominal pain. The urgency of the situation must not be missed as such a patient can deteriorate rapidly with septicaemia.

The abdomen is divided into nine areas for ease of description (***Figure 63.2***). These regions are demarcated by the midclavicular lines in the vertical axis and by the transpyloric and transtubercular lines in the horizontal axis. ***Figure 63.2*** also indicates some of the organs and pathological processes that commonly cause pain experienced in these regions.

EXAMINATION OF THE ABDOMEN

Abdominal examination must be preceded by a detailed general examination of the patient as a whole. Physical examination should be systematic using the following sequence: inspection, palpation, percussion and auscultation.

General examination

The patient must be lying flat with hips and knees extended but without causing distress (this may require provision of a pillow) and the abdomen should be adequately exposed.

While inspection of the abdomen is done in this position, for palpation hips and knees are flexed to ensure relaxation of abdominal muscles.

The examination should be performed sequentially, beginning with general inspection looking for evidence of weight loss, dehydration, pedal oedema, anaemia, jaundice or abnormal pigmentation. Examination of the hands may provide evidence of anaemia or chronic liver disease whereas examination of the head and neck may identify features indicative of liver disease or cervical lymphadenopathy (particularly left supraclavicular) suggestive of intra-abdominal malignancy. The patient's vital signs (heart rate, blood pressure, respiratory rate and body temperature) should be noted. In the elective setting the patient's weight and body mass index are also recorded.

Inspection

Scars, abdominal distension, visible peristalsis or abdominal masses, dilated veins, pulsation or abdominal wall swelling suggestive of hernia should all be carefully sought. The size and location of scars from previous surgery may provide some insight into the nature of the intervention that was performed (see ***Chapter 7***).

In an abdominal emergency look for Grey Turner's sign – skin discoloration of the flanks due to retroperitoneal haemorrhage in severe acute pancreatitis and leaking abdominal aortic aneurysm. Cullen's sign – discoloration around the umbilicus – may indicate severe acute pancreatitis, ruptured ectopic pregnancy or trauma to the liver. In these situations, blood tracks to the umbilicus along the ligamentum teres (***Figure 63.3***). These signs are better appreciated in a fair-skinned patient.

In a patient with acute abdominal pain, it is important to observe whether the abdominal wall moves with respiration. A thin patient with diffuse peritonitis may be unable to lie flat and the abdominal wall will have a 'scaphoid' appearance owing to protective contraction of the rectus abdominis muscles. It is often appropriate to ask the patient to cough gently – this will evoke sudden discomfort in the area of underlying peritoneal irritation (equivalent to eliciting rebound tenderness, but not as distressing for the patient). A visible 'cough impulse' will also help to identify an abdominal wall hernia, if present. A rounded, symmetrical contour of the abdomen with bulging flanks is seen in the presence of ascites. Visible abdominal masses, mobility on respiration and peristalsis are all best observed if the clinician kneels by the patient's bed so that the observer's eye is at the level of the patient's anterior abdominal wall. The same position is useful during palpation for abdominal masses (***Figure 63.4***).

Figure 63.3 Cullen's and Grey Turner's sign of skin discoloration of the flanks and around the umbilicus (courtesy of Mr Pradip Datta, Honorary Consultant Surgeon, Wick, Scotland).

Figure 63.4 Eye at the level of patient's abdominal wall.

In a thin patient, visible bowel loops give clues about the pathology: an overdistended, bean-shaped loop is seen in caecal volvulus, which characteristically points towards the left upper quadrant, and in sigmoid volvulus, which points towards the right upper quadrant.

Palpation

Palpation should be performed in a systematic manner, checking all nine regions of the abdomen (***Figure 63.2***). Palpation should start in the region furthest away from the site of pain and the patient instructed to let the examiner know if tenderness is elicited. The examination should be gentle and the hands warm. The patient's facial expression will immediately reveal discomfort. Superficial palpation is followed by deep palpation if tenderness will allow. To avoid 'poking' during palpation, the forearm is kept horizontal, the whole of the palm is kept lightly on the abdomen and hand movement is made only at the metacarpophalangeal joints; never at the interphalangeal

George Grey Turner, 1877–1951, Professor of Surgery, at the University of Durham (1927–1934) and at the Royal Postgraduate Medical School, Hammersmith Hospital, London, UK (1935–1946).

Thomas Stephen Cullen, 1868–1953, Professor of Gynecology, the Johns Hopkins University, Baltimore, MD, USA, described the sign in ruptured ectopic pregnancy in 1916.

joints of the fingers. Palpation during respiration is performed to identify the lower margins of the liver and spleen as they move with respiration. Palpation of the abdomen in a patient with ascites will often demonstrate a doughy feel in the tubercular abdomen.

Signs of parietal peritoneal irritation (tenderness, guarding, rebound tenderness, rigidity)

In the presence of abdominal pain, the degree of abdominal wall rigidity and involuntary guarding should be assessed. Guarding represents contraction of the abdominal wall muscles over the area of pain. This might occur 'voluntarily' when the patient wishes to avoid the pain from examination or 'involuntarily' when the muscles go into spasm as the inflamed viscus touches the parietal peritoneum. This produces a reflex spasm of the overlying abdominal wall muscles. The presence of rebound tenderness indicates underlying peritoneal inflammation and is examined best using gentle percussion, although pain on coughing is also found when there is rebound tenderness. When the underlying peritoneal inflammation becomes generalised, the abdomen is 'board-like rigid' to palpation, and selective tenderness can no longer be elicited. This sign represents widespread involuntary guarding.

Abdominal masses

A mass arising from the anterior abdominal wall will usually be mobile when the patient is relaxed. On contracting the abdominal wall muscles (ask the patient to lift his or her legs with the knees extended or perform Valsalva's manoeuvre for laterally placed swellings), lumps superficial to the abdominal wall muscles will become more obvious, and those attached to the deep fascia will become less mobile. Those arising within the muscle layer will become fixed and remain unchanged in size. Lumps arising deep to the abdominal wall (i.e. within the peritoneal cavity or behind the peritoneum) will become impalpable or less prominent on tensing the anterior abdominal wall muscles.

An intraperitoneal mass in contact with the diaphragm will move on respiration whereas retroperitoneal masses are usually fixed and do not move with respiration; an enlarged kidney is 'ballotable' and bimanually palpable. Normal aortic pulsations can be both seen and felt in a thin abdomen, but expansile pulsation is characteristic of an abdominal aortic aneurysm. This should be differentiated from transmitted pulsation of a mass sitting on the aorta (e.g. pseudocyst of the pancreas). When 'palpating during inspiration', the examining hand is placed distal to the normal site of the organ and is held there until the edge of the organ descends and touches the examiner's fingers. Liver, spleen, gallbladder and kidneys are best palpated during inspiration. An abdominal mass in a female, the lower limit of which cannot be distinguished, is likely to arise from the pelvis. If the mass can be moved in a transverse direction, it is likely to be a uterine or ovarian mass. The movement of a mesenteric cyst is perpendicular to the direction of attachment of the root of the mesentery.

Spleen

In a healthy patient the spleen is not normally palpable. An enlarged spleen descends downwards, forwards and medially. Palpation for an enlarged spleen is best performed in a supine patient. The examining hand should start in the right lower abdomen, with the tips of the fingers pointing upwards and pressed inwards. The patient is then asked to take a deep breath; if the spleen is enlarged the lower edge with the characteristic notch will touch the fingers. If it is not palpable, then the hand is gradually moved upwards in the direction of the position of the edge of the normal-sized spleen with each breath. If the spleen is still not palpable, the patient is moved to the right lateral position and the examination repeated.

Liver

In a supine patient, the hand is placed in line with the potential enlarged liver edge lateral to the rectus muscle. The patient is then asked to take a deep breath. If the liver is enlarged sufficiently below the costal margin, then surface irregularities can also be felt.

Percussion

Percussion helps to distinguish distension due to bowel gas from solid masses and free fluid in the abdomen. Percussion is most sensitive when the examiner moves from resonant parts of the abdomen to dull areas. In patients with free fluid in the peritoneal cavity, percussion from the centre to the periphery reveals dullness of flanks. Shifting dullness is elicited if the patient is re-examined lying on his or her side. The margin of dullness is then found to shift when the patient has moved. Free fluid can also give rise to 'fluid thrill'; this is feeling the vibrations from a tap in one flank on the other flank while pressure is kept on the midline to prevent vibrations through the abdominal wall.

Percussion is also a very sensitive and refined method of testing for rebound tenderness. If the patient winces with pain on abdominal percussion it denotes underlying peritonitis.

Auscultation

High-pitched bowel sounds are heard during the early stages of mechanical intestinal obstruction. Aortic and iliac bruits are heard when blood flows through a stenosis. A succussion splash is a sound like 'shaking a half-filled bottle with water' and is found most often in patients with gastric stasis due to gastric outlet obstruction. In generalised peritonitis and paralytic ileus, bowel sounds will not be heard or be very few and far between.

Inspection of hernia sites, examination of genitalia, inspection of anal region and digital rectal examination

Abdominal examination is not complete until all external hernia sites and the anal area have been carefully inspected,

Antonio Maria Valsalva, 1666–1723, Professor of Anatomy, Bologna, Italy, of whom Morgagni wrote 'there is nobody of those times who goes ahead of him, very few who are his equals'.

the genitalia, renal angles and the thoracic and lumbar spine are examined and a digital rectal examination performed. A vaginal examination may also be needed in females. Details of these clinical examinations are covered in the respective chapters.

VALUE OF OBSERVATION AND REVIEW

In the case of acute abdominal pain, there will be a subset of patients in whom, after full clinical assessment, the surgeon remains uncertain about the need for an urgent operation. This is probably the most difficult group to deal with compared with those in whom an urgent operation is either clearly required or clearly not required, and undoubtedly the one in which the majority of errors occur. These include rare causes of abdominal pain and vomiting such as metabolic diseases (diabetic ketoacidosis, diabetic gastroparesis, porphyria, hyperparathyroidism etc.), referred pain from the spine, heart and lungs and functional pain. Further urgent investigations are obviously needed in this group and these are discussed in some detail elsewhere in this book. However, while these are taking place, regular review of the patient is essential, preferably by the same clinician who initially examined the patient so as not to miss any subtle changes or worsening of the situation. Such a period of observation is an integral part of the early management of patients with acute abdominal pain.

FURTHER READING

Das S, Das S. *A manual on clinical surgery,* 14th edn. Kolkata: Das Publications, 2019.

Lumley JS, D'Cruz AK, Hoballah JJ, Scott-Connor CE. *Hamilton Bailey's demonstrations of physical signs in clinical surgery,* 19th edn. London: CRC Press, 2016.